Measurement of Joint Motion

A guide to Goniometry

2020 국시문제

62. 어깨관절 굽힘의 관절운동범위 측정 시 각도계 축의 위치는?

① 어깨뼈가시
② 복장뼈 앞면
③ 위팔뼈큰돌기
④ 팔꿈치머리돌기
⑤ 봉우리돌기 가쪽면

2021년 국가고시 출제문제

62. 엉덩관절 벌림의 관절운동범위 측정 시 각도계 축의 위치는?

① 큰돌기
② 궁둥뼈가시
③ 위앞엉덩뼈가시
④ 넙다리뼈 가쪽위관절융기
⑤ 넙다리뼈 안쪽위관절융기

2021년 국가고시 출제 문제

64. 다음에서 측정하는 어깨관절 움직임은?

- 시작 자세: 어깨관절 90° 벌림과 팔꿉관절 90° 굽힘 자세
- 축: 자뼈 팔꿈치머리
- 고정팔: 지면과 수직(또는 시상면과 평행)
- 운동팔: 자뼈의 정중선과 평행

① 폄
② 벌림
③ 엎침
④ 가쪽돌림
⑤ 수평벌림

2022 국가고시 문제

62. 어깨관절 벌림 관절운동범위 측정 시 각도계 축의 위치는?

① 부리돌기
② 어깨뼈가시
③ 팔꿈치머리
④ 어깨뼈봉우리
⑤ 결절사이고랑

2023 국가고시

63. 관절의 움직임과 관절각도계 축의 위치가 바르게 연결된 것은?

① 팔꿉관절 폄 – 안쪽위관절융기
② 손목관절 노쪽치우침 – 알머리뼈
③ 노자관절 뒤침 – 자뼈 붓돌기 손등면
④ 엉덩관절 안쪽돌림 – 위앞엉덩뼈가시
⑤ 어깨관절 수평벌림 – 팔꿈치머리

2024 국가고시 1교시

- 63. 관절의 운동과 각도계의 운동팔 배체가 옳게 연결 된것은 ?

1. 목돌림 – 1코끝을 따라 평행
2. 무릎관절폄 – 정강뼈 정중선과 평행
3. 손목관절 노쪽치우침 – 둘째 손허리뼈 정중선과 평행
4. 엉덩관절 모음 – 양쪽 위앞엉덩뼈 가시를 잇는 가상의 선과 평행
5. 노자관절 엎침 – 손바닥쪽 자뼈 붓돌기와 노뼈 붓돌기를 잇는 가상의 선과 | 평행

2025년 국가고시 1교시

- 62. 아랫팔 뒷침 관정운동 범위 측정시 각도계의 위치는

1. 노뼈 붓돌기 손등면
2. 자뼈 붓돌기 손등면
3. 노뼈 붓돌기 손바닥면
4. 자뼈 붓돌기 손바닥면
5. 손허리 손가락 관절 손등면

2025년 국가고시 1교시

- 63. 다음에서 측정하는 관절운동 범위 검사는 ?
- 시작자세 : 어깨관절 90 벌림과 팔꿉관절 90 굽힌상태로 앉는다.
- 각도계축 :팔꿈치 머리
- 고정팔: 바닥과 수직
- 운동팔:자뼈 붓돌기 정중선과 평행

1. 폄
2. 모움
3. 굽힘
4. 수평모음
5. 안쪽돌림

2025년 1교시

- 64. 엉덩관절 벌림 관절운동 범위 측정과 관련된 설명으로 옳은것은 ?

1. 축은 넙다리 큰돌기이다.
2. 정상관절 운동범위는 25도 이다.
3. 엉덩관절 안쪽돌림 자세에서 측정한다.
4. 시작자세는 검사대에 걸터앉은 자세이다.
5. 고정팔은 양쪽 앞위 엉덩뼈 가시를 잇는 가상의 연결선이다.

Shoulder flexion：165–180
Fulcrum：greater tubercle
Proximal arm： midline of thorax
Distal arm：midline of the humerus

Shoulder extension: 50–60

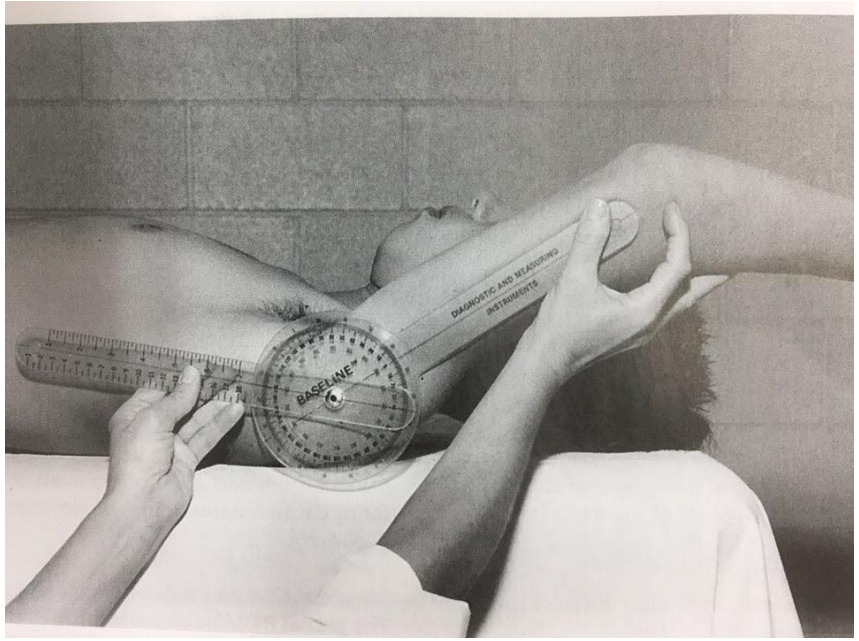

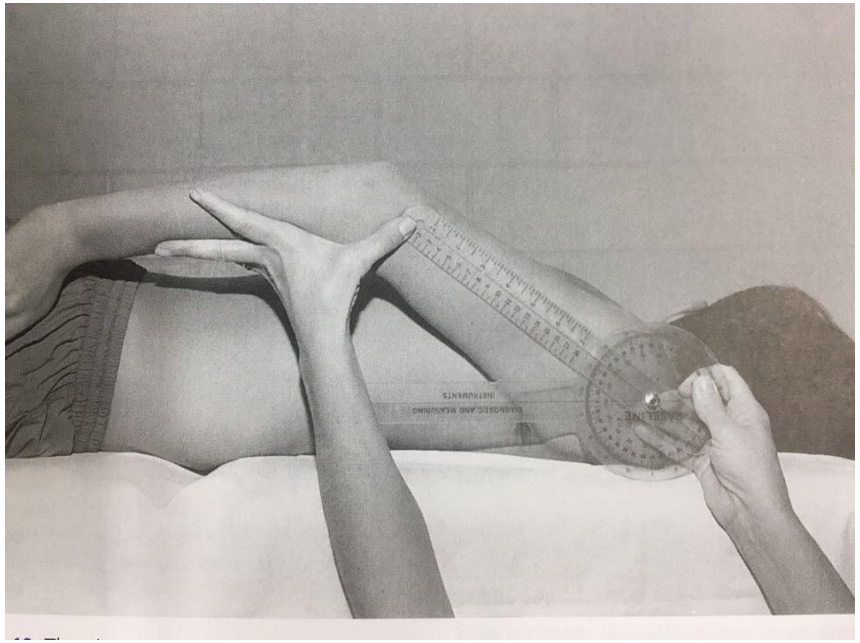

Shouldr int rotation: 70–90

Fulcrum ：olecranon process

Proximal arm：vertical with the floor

Distal arm：ulnar styloid process

Shoulder ext rotation :90 –100

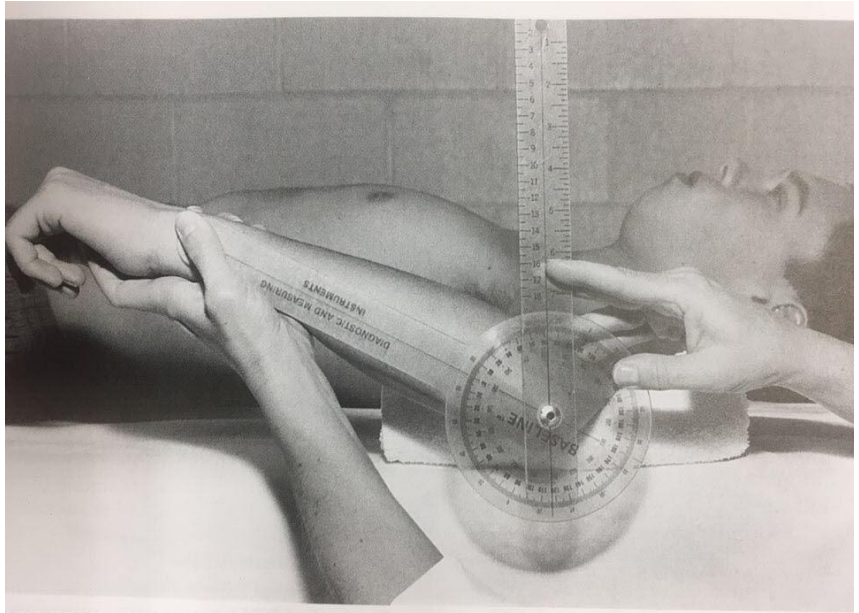

URE 4.28 The alignment of the goniometer at the end of medial rotation ROM of the

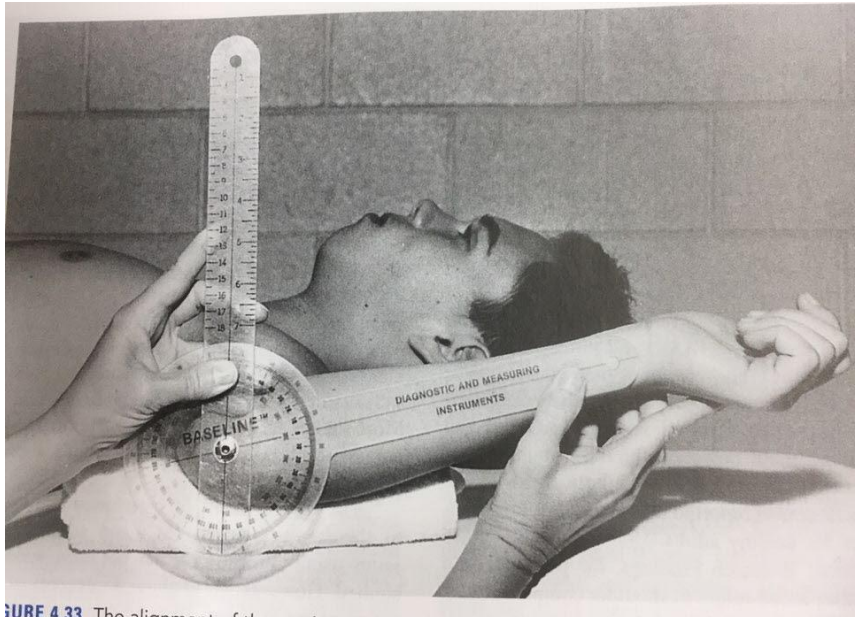

GURE 4.33 The alignment of the goniometer at the end of lateral rotation ROM of the

Shoulder abduction: 170–180

Fulcrum：anterior acromion process

Proximal arm： sternum

Distal arm：midline humerus

Elbow flexion: 140–150

Fulcrum: lateral epicondyle

Proximal arm：midline humerus

Distal arm：midline radius

not prevent full elbow extension.

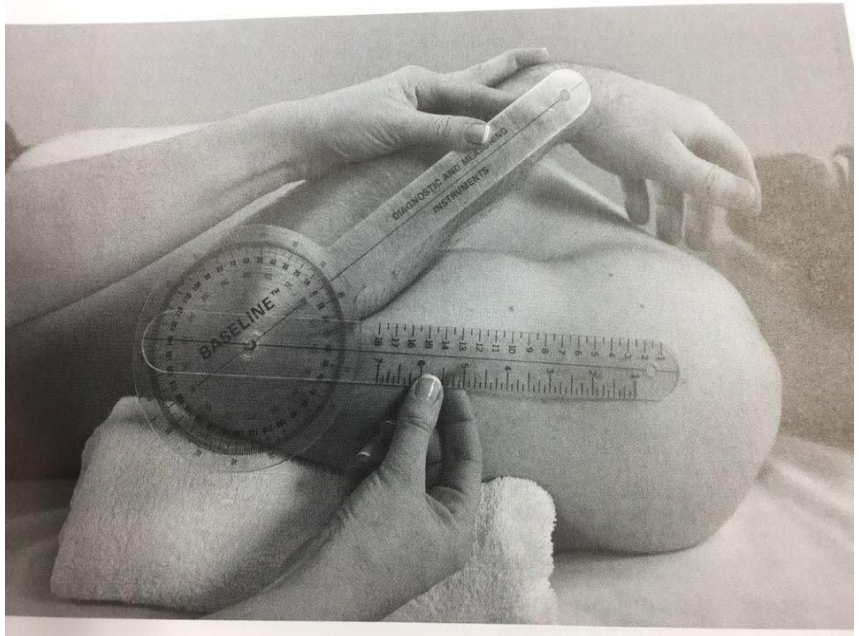

Alignment of the goniometer at the end of elbow flexion ROM. The

Wrist flexion: 60–80

Fulcrum : lateral triquetrum

Proximal arm: midline ulna

Distal arm: midline fifth metacarpal

Fulcrum : capitate

Proximal arm : midline forearm

Distal arm : third metacarpal

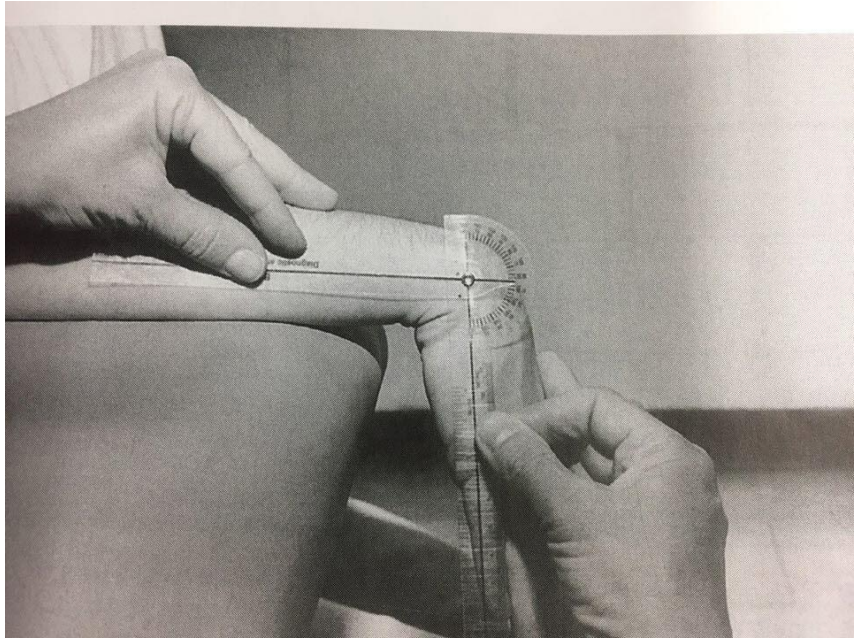

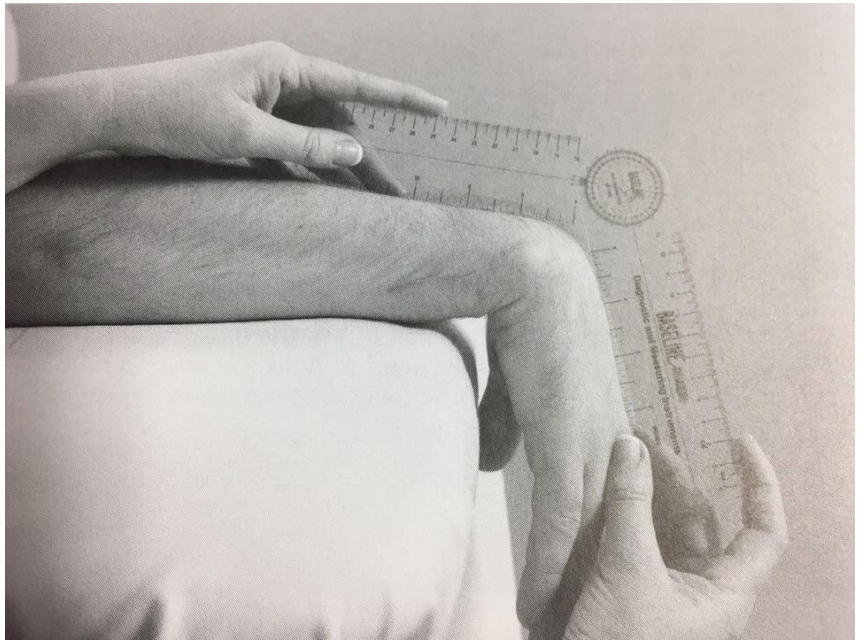

Wrist extension: 60–75

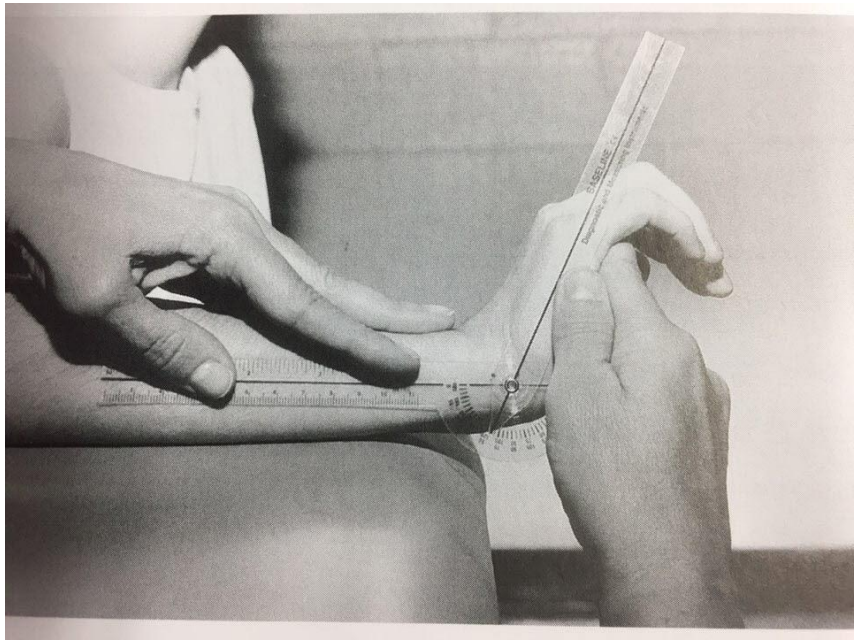

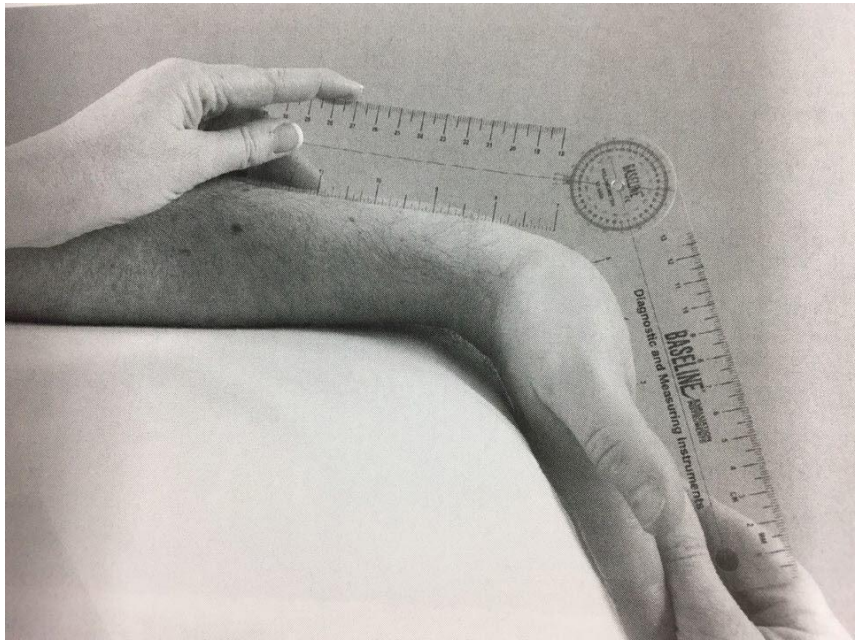

Wrist deviation

Ulnar drviation : 30–45

Radial deviation: 20–25
Fulcrum ; over the capitate
Proximal arm: midline forearm
Distal midline of third metacarpal

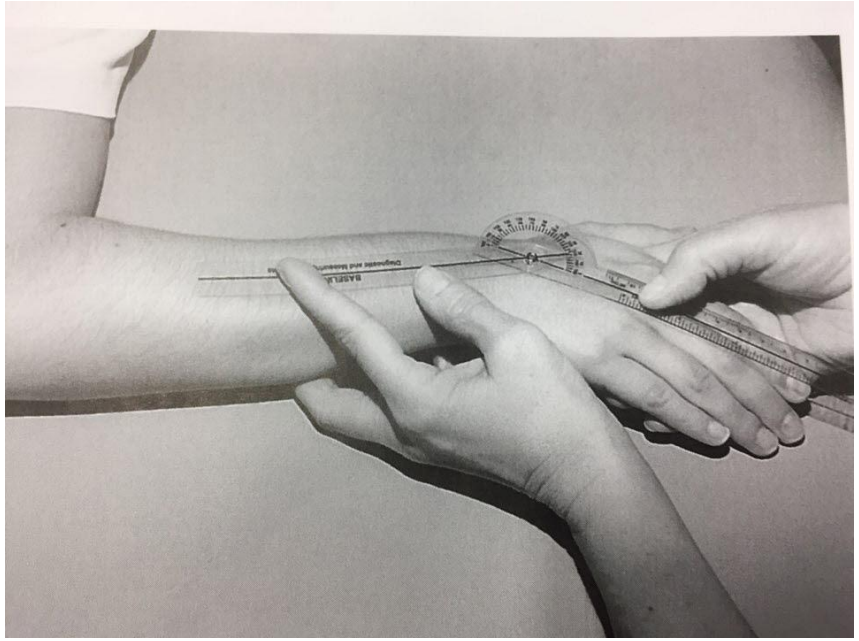

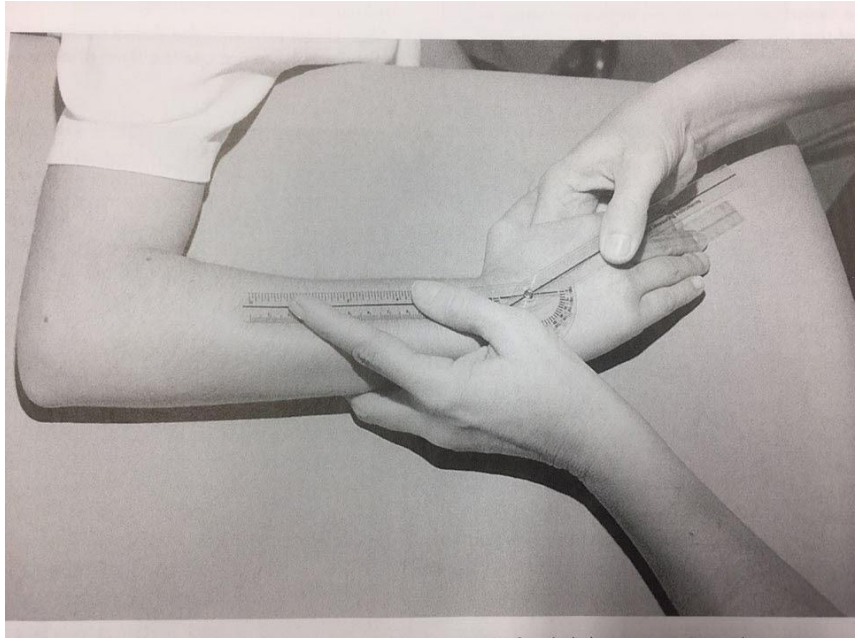

Hip flexion: 120–140
Fulcrum: greater trochanter
Proximal arm: midline pelvis
Distal arm:midline femur

Hip extension:18–30

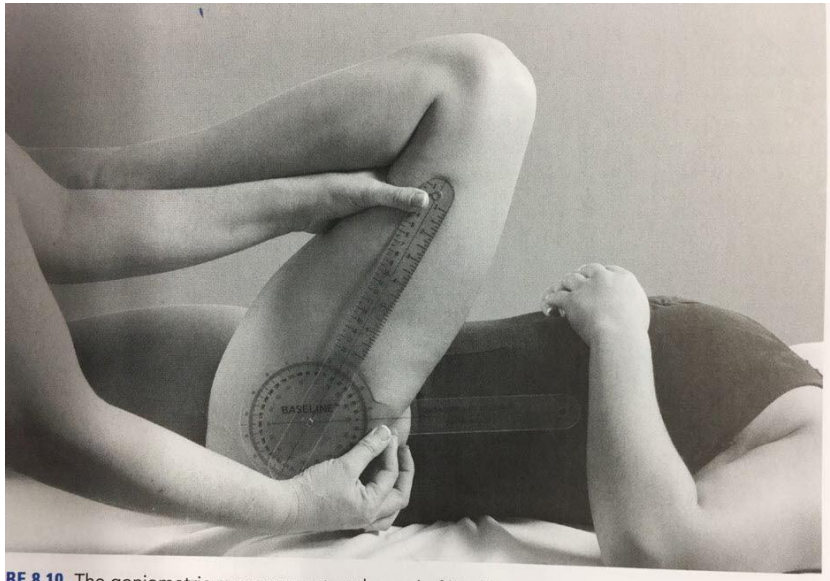

RE 8.10 The goniometric measurement at the end of hip flexion ROM. The examiner one hand to align the distal goniometer arm and to maintain the hip in flexion. The iner's other hand shifts from stabilizing the pelvis to hold the proximal

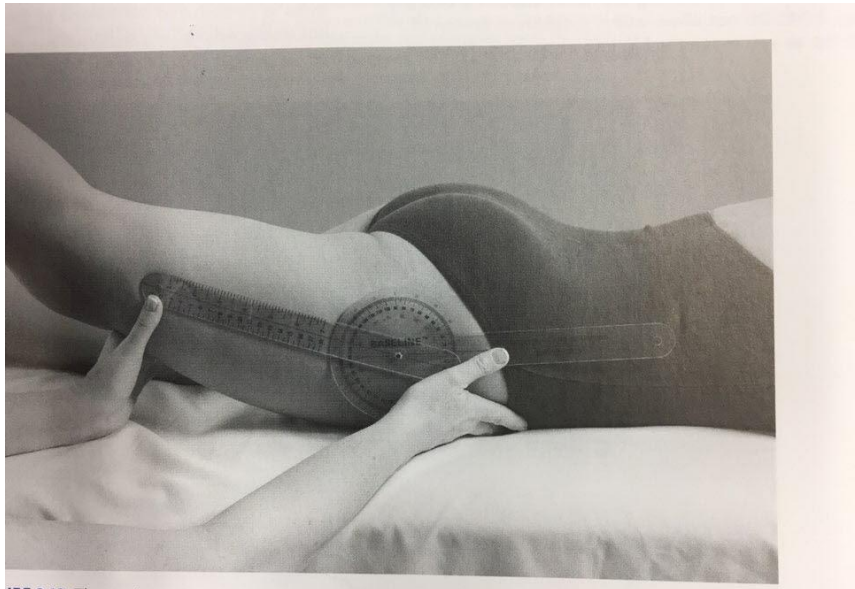

URE 8.13 The goniometric measurement at the end of hip extension passive ROM. The miner uses one hand to hold the proximal goniometer arm in alignment. The examiner's er hand supports the femur and keeps the

Hip abduction:40–55

Fulcrum: ASIS

Horizontal line ASIS

Midline femur

Ideally, the goniometer will have two scales and the start position can be read as 0 degrees or 90 degrees. If there is only one scale, the examiner must do math to transpose the reading from 90 degrees to 0 degrees. For example, an actual reading of 90 to 120 degrees on the goniometer will be recorded as 0–30 degrees.

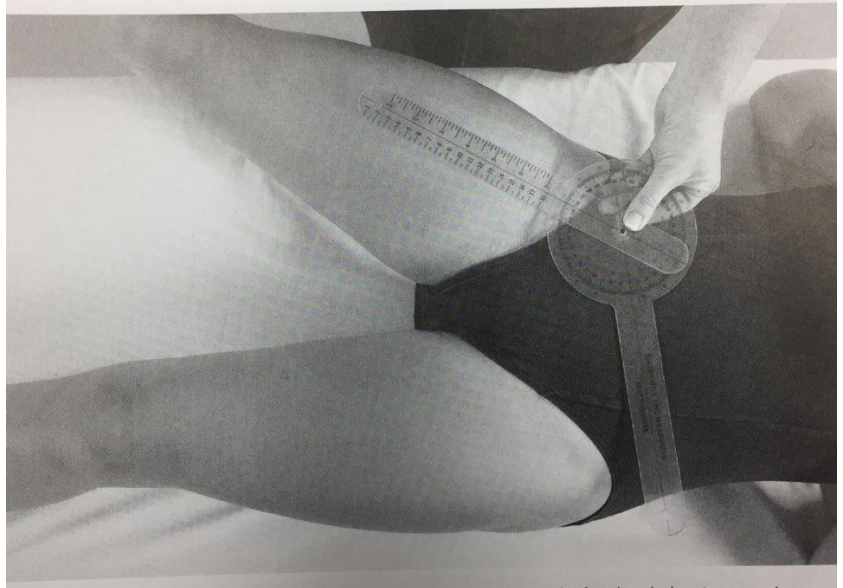

FIGURE 8.16 The goniometric measurement indicating the end of right abduction passive ROM. The examiner has determined the end-feel and has moved the right hand from stabilizing the pelvis to hold the goniometer in correct alignment. The examiner may also place the individual's index fingers over the right and left ASIS to help assure accurate

Hip adduction:20–25

he reading from 90 degrees to 0 degrees. For example, an actual reading of grees will be recorded as 0–30 degrees.

19 The goniometric measurement indicating the end of the right hip adduction OM. The examiner uses one hand to hold the fulcrum of the goniometer over dual's anterior superior iliac spine. The examiner prevents hip rotation by ng a firm grasp at the individual's lower leg with the other hand.

Hip int rotation: 30–45
Patella
Perpendicular to floor
Midline lower leg

Hip ext rotation: 32–50

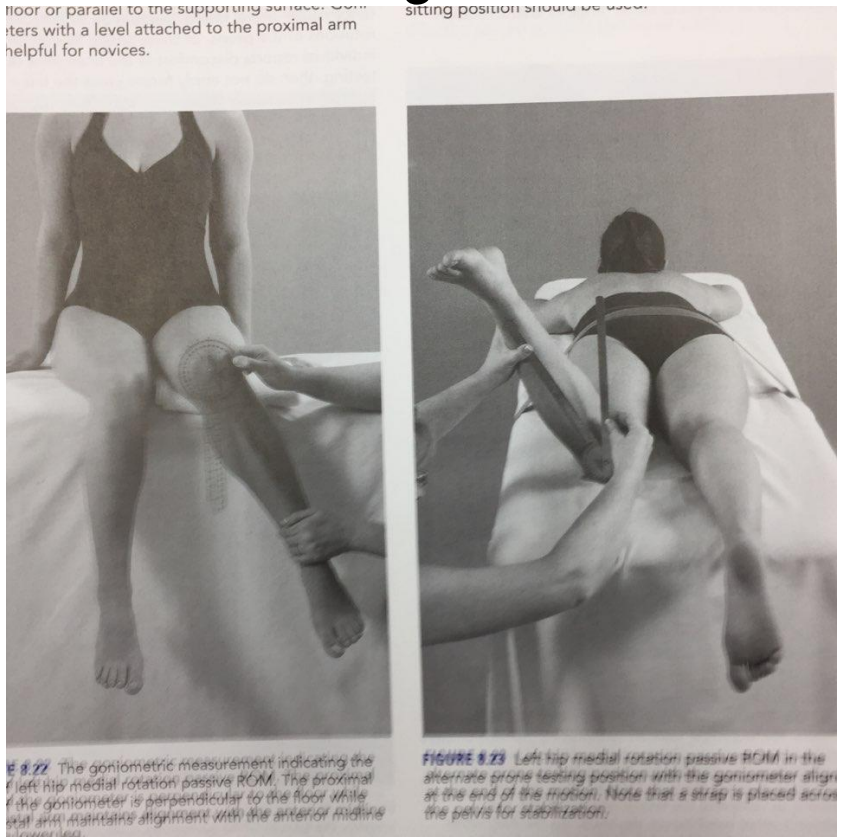

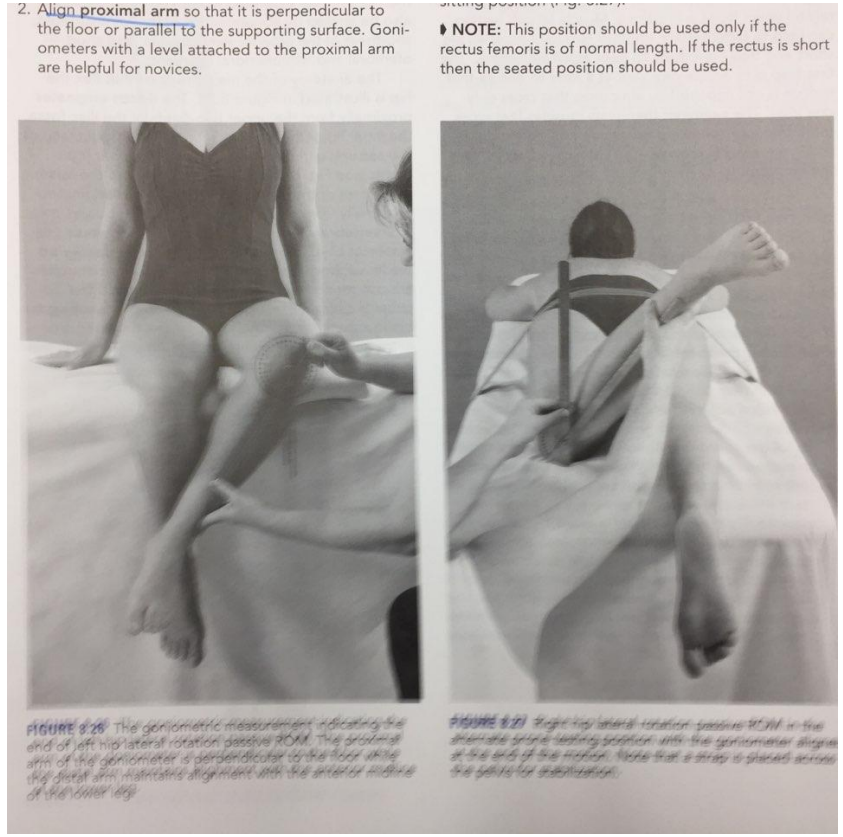

SLR : length of hamstring: 68–80
Greater trochanter
Midline pelvis
Midline femur

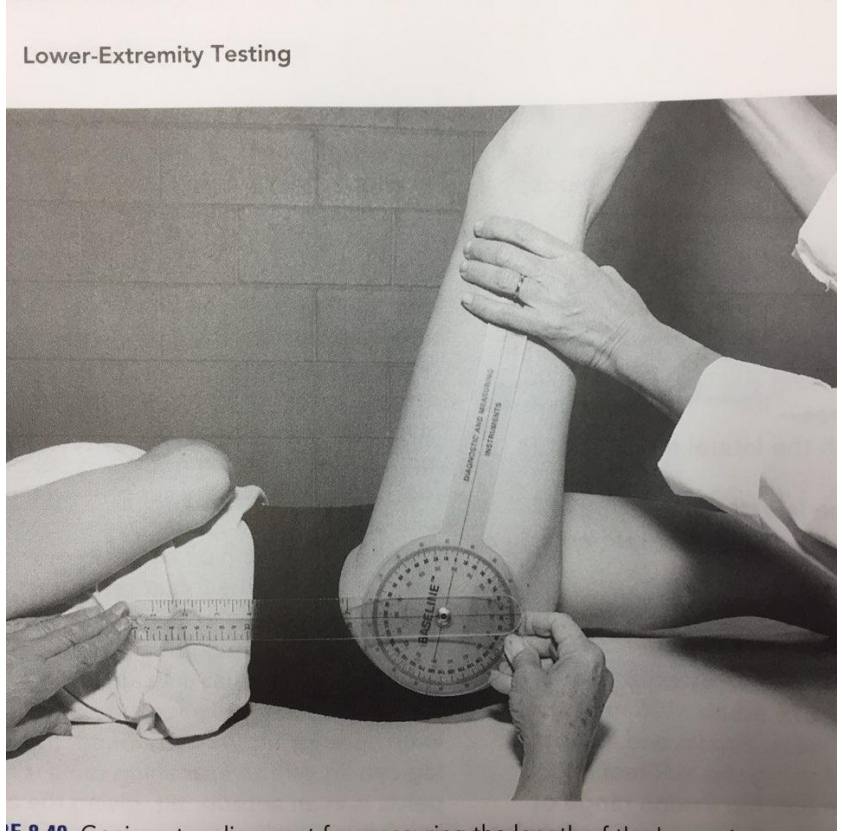

Knee flexion: 130–140

Lateral epicondyle femur

Midline femur

Midline fibula

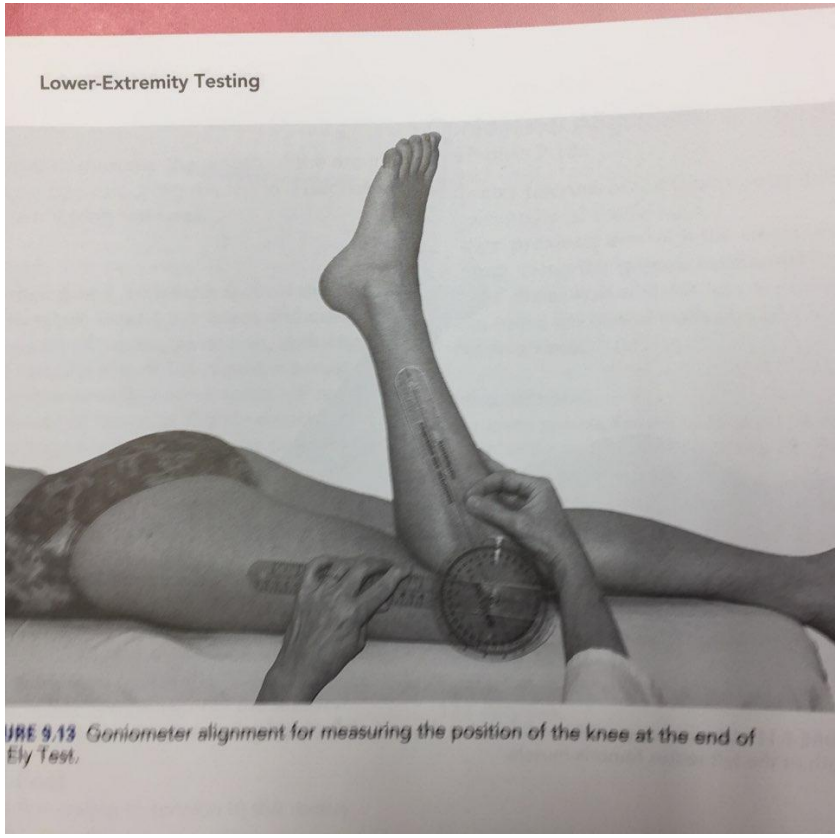

Ankle dorsiflexion: 15–20

Lateral malleolus

Midline fibula

Parallel fifth metatarsal

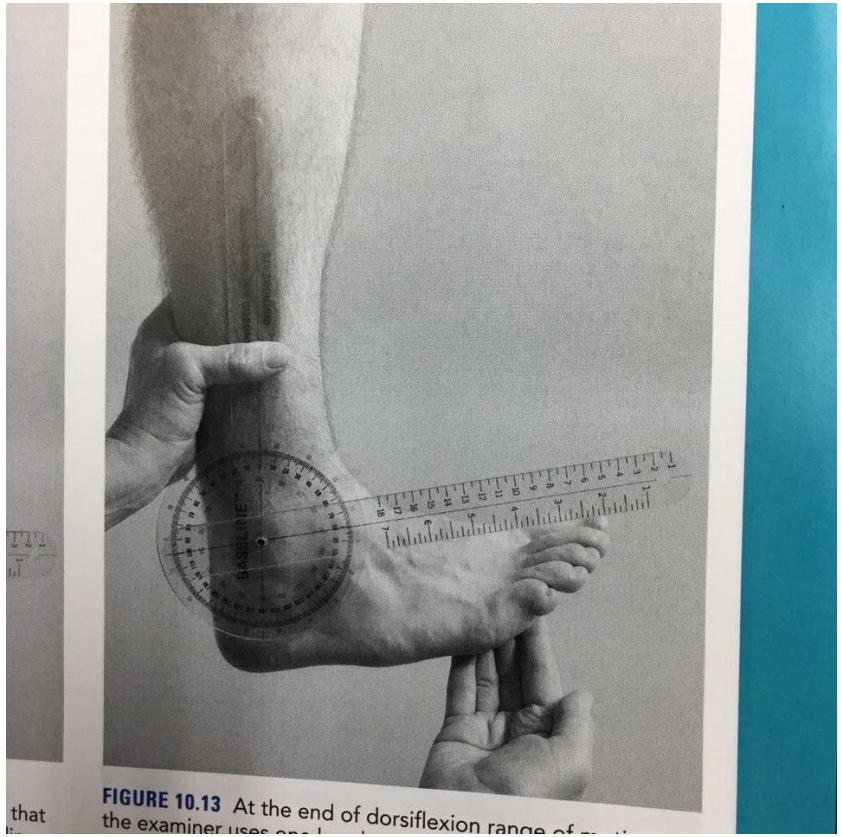

FIGURE 10.13 At the end of dorsiflexion range of

Ankle plantar flexion: 45–55

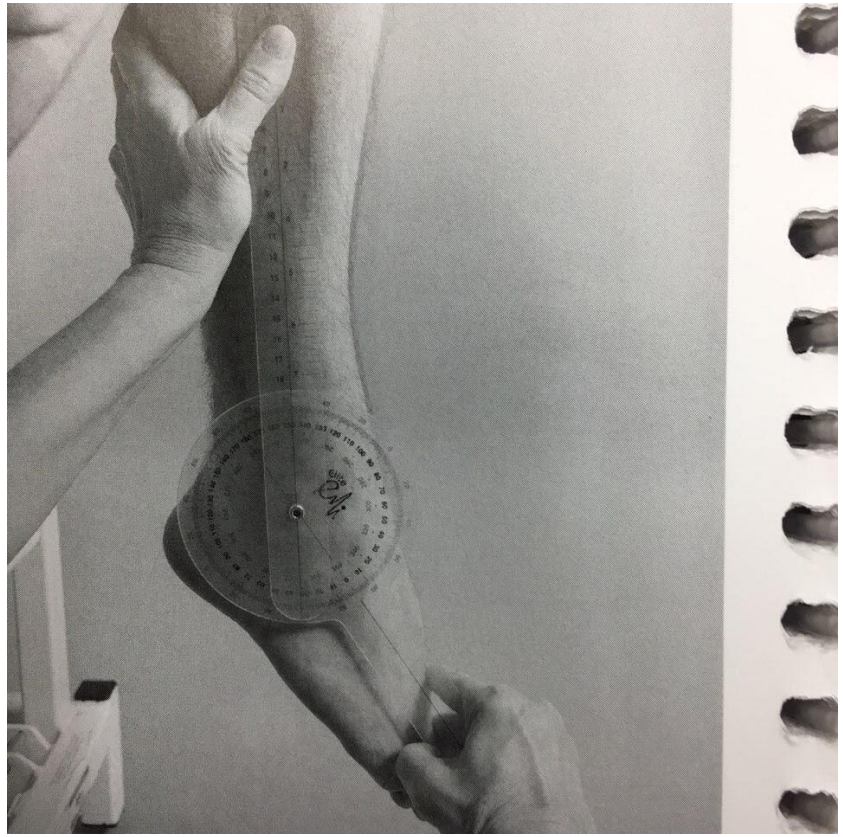

Inversion: 30–35

Mid malleoli

Midline lower leg

Midline 2 nd metatarsal

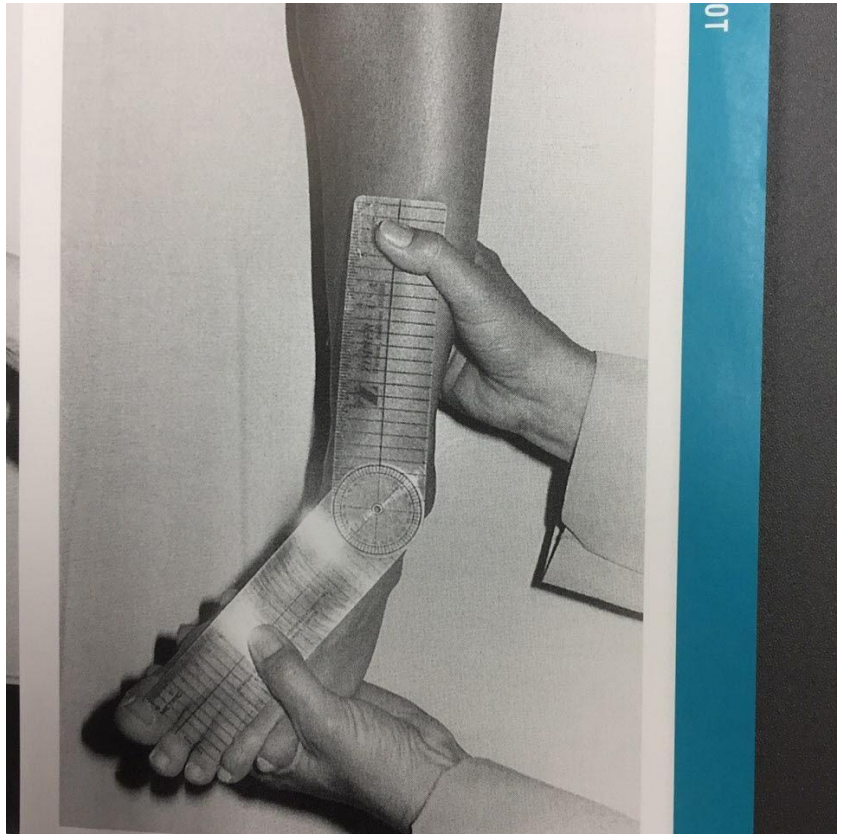
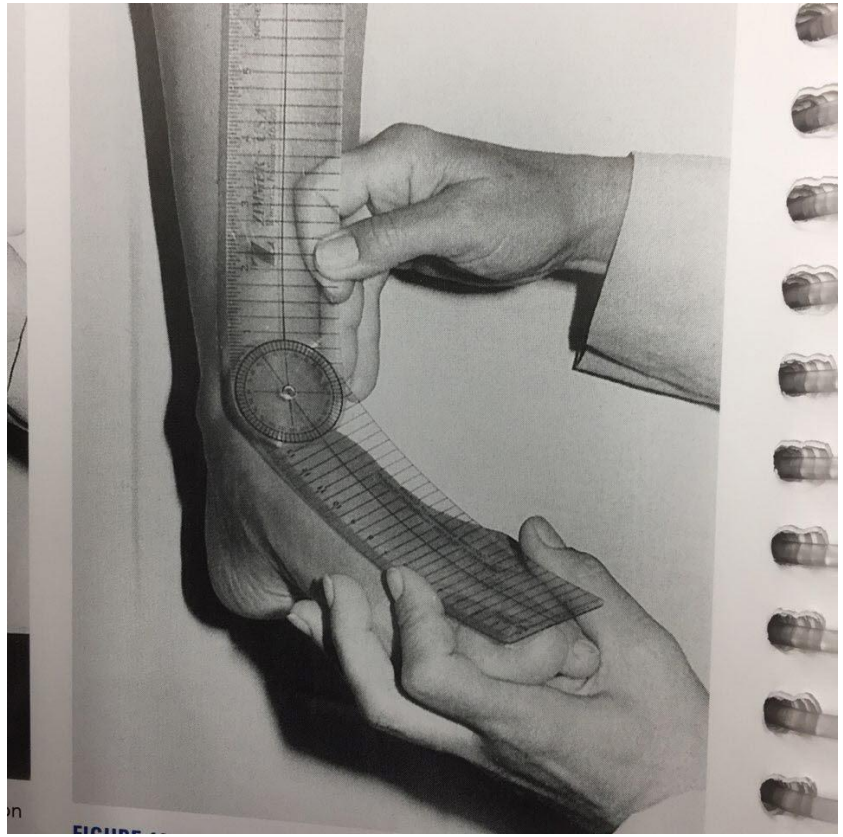
Eversion; 15–20